

Ophthalmic Images

A Case of Unilateral Phthiriasis Palpebrarum Infestation

Yingjuan Lv, MD; Xiaoli Xing, MD; Wenjiang Ma, MD

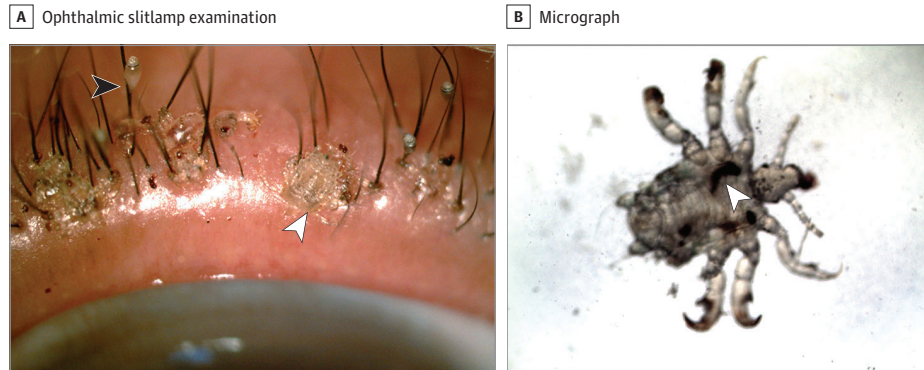


Figure. A, Ophthalmic slitlamp examination. Ophthalmic slitlamp examination shows phthirus pubis (crab lice) (black arrowhead) and nits (white arrowhead) on the eyelashes in the left eye. B, Low-power light micrograph. A low-power light micrograph showing a louse with ingested blood (arrowhead).

A 62-year-old woman with a history of raising dogs presented with itching of her left eyelids for 2 weeks. Slitlamp examination revealed lice and translucent ovoid nits on the eyelashes (Figure, A). There was no infestation of hair in other body regions. Based on the examination findings (Figure, B), a diagnosis of unilateral phthiria-

sis palpebrarum was made. Mechanical removal of the lice was attempted but not successful so the affected eyelashes were removed. The eyelids were then treated with 1 yellow mercuric oxide ointment, %, twice per day for 2 weeks, with resolution of the infestation.

ARTICLE INFORMATION

Author Affiliations: Eye Institute and School of Optometry and Ophthalmology, Tianjin Medical University Eye Hospital, Tianjin, China.

Corresponding Author: Yingjuan Lv, MD, Eye Institute and School of Optometry and Ophthalmology, Tianjin Medical University Eye Hospital, No. 251 Fu Kang Rd, Nankai District, Tianjin 300384, China (lvyingjuan@tmu.edu.cn).

Conflict of Interest Disclosures: None reported.

Additional Contributions: We thank the patient for granting permission to publish this information.